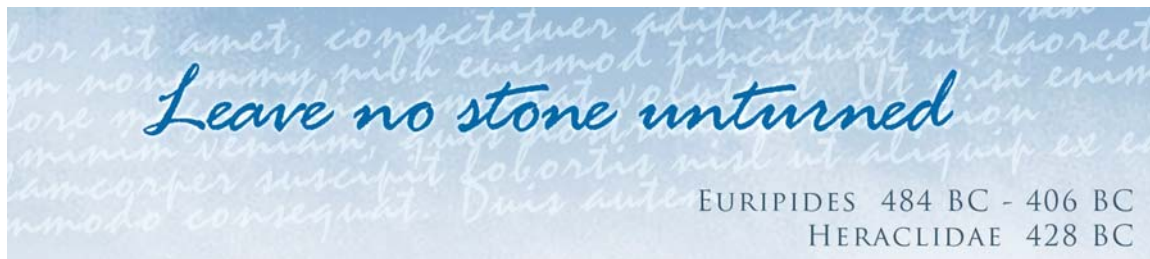



Minnehaha Falls - Minnesota

Stones form from crystalline aggregates in the urine
They often present with acute ureteric colic



Stone disease is known as urolithiasis or nephrolithiasis. The medical word for a stone is calculus. Stones occur in the upper urinary tract and in the bladder. Most are radio-opaque and therefore show on xrays.

Incidence

The overall prevalence of stones in the UK is approximately 3%. For every 2 females with stones there are 5 males. The majority of stones in the UK and developed world are in the upper urinary tract. Bladder stones are predominant in the developing world. Over 80% of stones are unilateral. The overall incidence of stones is increasing. The prevalence in America is 12%.

Causes

The vast majority of stones (90%) are idiopathic (no known cause).

Identifiable causes include

- Infections
- Urinary stasis
- Increased urinary metabolites

Pyelonephritis is an infection of the kidney. It can predispose to renal stones. *Proteus mirabilis* and *Klebsiella* are two bacteria which produce urinary tract infections. Both these organisms split urea into ammonia making the urine more alkaline. This chemical reaction produces struvite stones. Schistosomiasis is a parasitic fluke infestation that gives rise to bladder stones. Foreign bodies such as catheters left in for too long irritate the lining to produce stones.



Minnehaha Falls - Minnesota

Stasis causes stones by allowing the crystals to precipitate out more easily. This can occur in the kidney from ureteric obstruction from any cause. Pelvi ureteric junction obstruction (PUJO) is a congenital abnormality where the exit of the kidney is narrowed. The resultant hydronephrosis (dilatation of the urine collecting system) leads to stasis. In medullary sponge kidneys the ducts conveying the urine from the filtration units to the renal pelvis are dilated. This relatively sluggish flow of the urine leads to multiple small stones in the kidney medulla. Bladder stones occur with bladder outflow obstruction.

Increased metabolites in the urine lead to supersaturation. Increased urinary concentrations of urates (hyperuricuria) occur in gout. Hyperuricuria also occurs following chemotherapy for leukaemia. These give rise to urate stones. Hypercalciuria is too much calcium in the urine. This can occur in conditions such as primary hyperparathyroidism (this is an endocrine disorder of the parathyroid gland producing too much calcium in the blood and subsequently in the urine). Most cases of hypercalciuria are idiopathic. Cystinuria is a rare metabolic disorder that is inherited through a recessive gene. Cystine stones are very hard and difficult to disintegrate.

Other conditions associated with stones include sarcoidosis and Crohn's disease of the bowel. Astronauts in space have an increased risk of stone formation. They put no stress on their bones because of the zero gravity. This demineralises the bones.

It has been postulated that stones may form in the presence of abnormal urinary tract mucoproteins. It has also been suggested that stone inhibitory substances may be lacking.



Minnehaha Falls - Minnesota

Types

Calcium oxalate stones

80% of stones

These are radio-opaque and show on an xray

They are dark brown

Calcium/magnesium phosphate stones

10% of all stones

Radio-opaque

Light brown in colour

Struvite stones

Formed from infections

Uric acid stones

Up to 10% of all stones

Radiolucent and do not show on an xray

Cystine stones

Rare

Radio-opaque

Presentation

Some stones may be totally asymptomatic (without symptoms).

Pain is a common way for stones to present. Ureteric colic starts suddenly with pain in the loin (flank). The pain radiates round to the front of the abdomen and down to the groin. It can also radiate into the testicle. The pain is very severe. The patient is very restless and uncomfortable and will want to pace the room. Typically each episode will last 30 to 60 minutes. It tends to come and go with an hour or two between attacks. The pain is so severe that the patient may have nausea and vomiting. There may be a temperature if there is an associated urinary tract infection.

Larger stones in the renal pelvis of the kidney may present with a dull ache in the loin. These stones can fill the renal pelvis and are referred to as staghorn calculi due to the similarity to antlers.

Abdominal examination may not reveal any abnormality despite the severe pain. The patient may have a temperature if there is an infection.



Differential Diagnosis

Stones may be confused with the following

- Pyelonephritis
- Abdominal aortic aneurysm
- Appendicitis
- Biliary colic (gallstones)
- Peritonitis
- Diverticulitis
- Salpingitis
- Torted ovarian cyst
- Ectopic pregnancy
- Shingles

Investigations

Blood tests

A full blood count measures the white blood cells in the blood. This is raised in infection.

Serum calcium can be measured.

Urea and creatinine assesses renal function

Urine tests

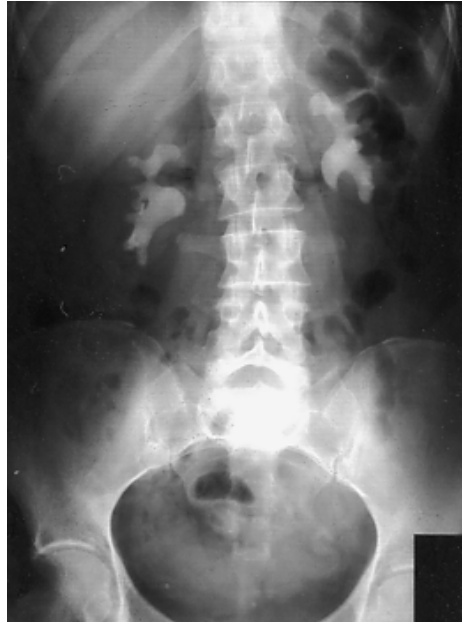Urine dipstick will reveal haematuria (blood in the urine). The vast majority of stones will have microscopic haematuria.

MSU (mid stream specimen of urine) will detect infection.

24 hour urine collections to measure output of calcium urate or Cystine

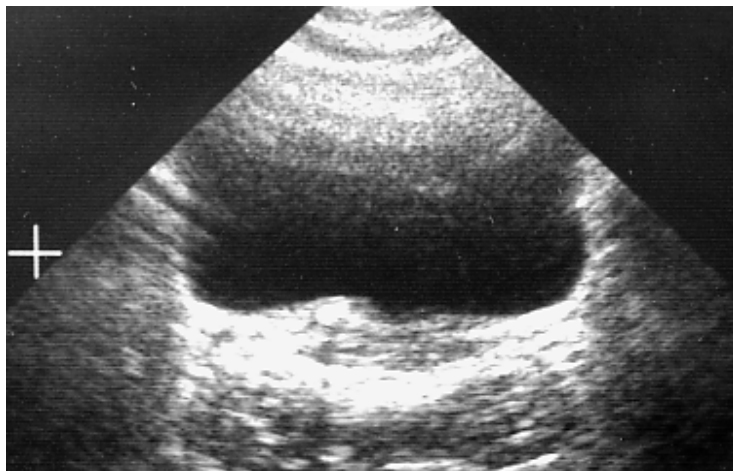
Radiology

KUB (Kidney Ureter and Bladder plain xray). 90% of stones are radio-opaque and can be seen on an xray.



KUB Xray – Bilateral Staghorn stones

IVU (IntraVenous Urogram) is a series of xrays following the injection of xray contrast dye. It will show stones and any obstruction. It is thought to be about 92% accurate. Spiral CT is a CT scan taken in a helical way. This is the most accurate method of detecting stones. Retrograde ureterography is performed in doubtful cases. Dye is injected up the ureter at cystoscopy. Stones are seen as filling defects in the ureter. Ultrasound is not routinely used to diagnose stones but stones are occasionally picked up. It is however used to visualise stone during ESWL.



Ultrasound - Stone at lower end of ureter

Stone

Any recovered stone should be analysed biochemically.

Further investigations

A raised serum calcium (hypercalcaemia) needs further investigations. Primary hyperparathyroidism is one cause which can be cured with an operation called a parathyroidectomy. A raised serum uric acid is treated with Allopurinol. This is an enzyme inhibitor which stops the production of uric acid.

Treatment

Medical

Analgesia. Pain relief is paramount. Pethidine used to be the gold standard. Because it is a narcotic agent its use is switching more and more to the non steroidal anti inflammatory group of drugs. A common choice is diclofenac which has proved more effective than pethidine in trials.

Anti emetics are important to control nausea and vomiting.

Fluid intake will assist the flushing of the stone. Sometimes too much fluid may hamper ureteric peristalsis and hence the passing of the stone. Too much may also increase any hydronephrosis secondary to an impacted stone.

All the urine is sieved to catch the stone when it passes.



Surgical

If sepsis is present proximal to an impacted stone then conservative management should be abandoned. Percutaneous nephrostomy may be necessary to drain the kidney. This is a small calibre tube inserted through the skin into the kidney. It is done under CT or ultrasound guidance. This will prevent a pyonephrosis developing (pus in the renal pelvis).

The surgical management of the stone depends on the site of the stone, its size and whether it is causing any obstruction.

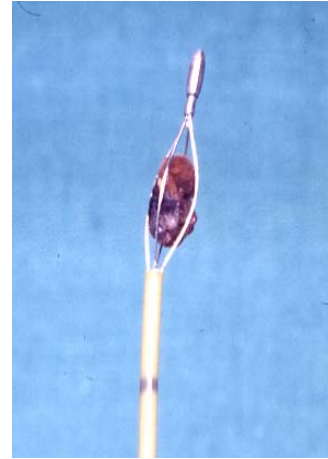
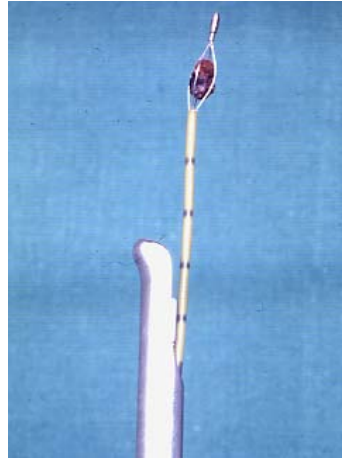
Renal pelvis stones

ESWL

As the name suggests Extracorporeal Shock-Wave Lithotripsy focuses shock waves into the kidney from a source outside the body. The shock waves are produced by electrohydraulic, piezoelectric or electromagnetic elements. The shock waves disintegrate the stone and powder it. This disintegration is colloquially referred to as “banging” the stone. The stone is treated in situ and the patient is left to pass the fragments subsequently. It is performed as a day case procedure with pre op analgesia. This treatment is not suitable for patients taking blood thinning drugs such as Warfarin or Plavix.

Ureteroscopy

A ureteroscope is a long telescope (rigid or flexible) that is passed up the ureter via the bladder. The ureteric orifice at the lower end of the ureter often needs to be dilated prior to the insertion of the ureteroscope. It is usually carried out under general anaesthesia. Wire baskets (Dormia baskets and Sigura baskets) are often used to capture a stone via the ureteroscope or the cystoscope. Laser lithotripsy is used with the flexible ureteroscope to disintegrate stones in the kidney under direct vision. Laser machines are expensive which precludes many units from having this equipment.



Stone in Dormia basket at cystoscopy and close up

Percutaneous Nephrolithotomy

In this technique a telescope (nephroscope) is passed through the skin into the renal pelvis. A needle is placed in the renal pelvis under ultrasound or xray control. A guide wire is then inserted which is used to dilate a tract for the insertion of the nephroscope. Stones can be extracted or disintegrated under direct vision. Electrohydraulic or ultrasound disintegrator probes are used.

Open Pyelolithotomy

This is an operation performed when ESWL or percutaneous nephrolithotomy have failed. It is also done when the patient requires a repair procedure on the kidney such as a pyeloplasty (an operation to correct a pelvi-ureteric junction obstruction). The incision is in the line of the lower ribs at the back.

Stenting

A stent is a soft tube inserted into the ureter to relieve an obstruction. The stents used are called double J stents because there is a pig tail at each end. The stent is positioned in the ureter under xray control. The pig tails help to keep the stent in position in the kidney and the bladder. Stents are used to bypass an obstructing stone and used pre ESWL for larger stones. This prevents larger fragments of stone passing down the ureter.



Ureteric Stones

The position of the stone determines which treatment modality is used.

Upper third ureteric stones

ESWL is the preferred method. This can be done in situ or the stone can be manipulated back into the renal pelvis. Flushing or dislodging the stone with a catheter are the methods used. This technique is often termed a “push-bang”. Double J stents are sometimes used to prevent obstruction. The stents are not used on every patient.

Middle third ureteric stones

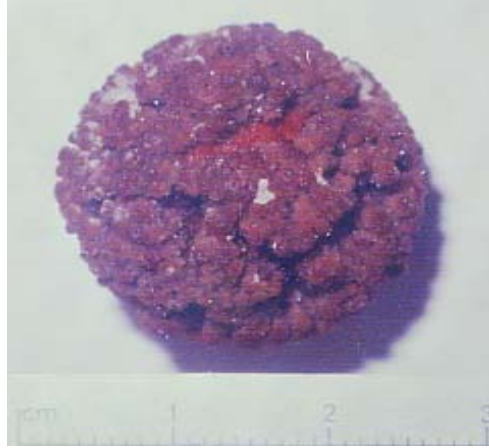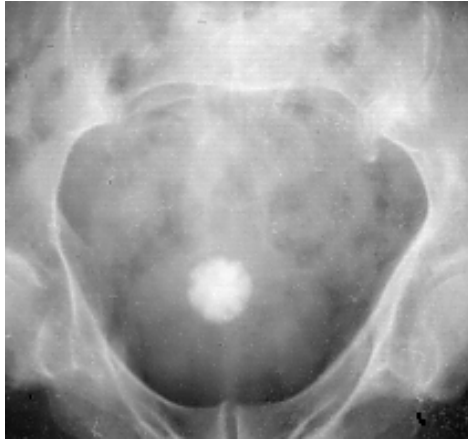These stones are the most difficult to treat. Pushing the stone back into the kidney is more difficult than in upper third stones. ESWL is dependent on localising the stone in the ureter with xrays or ultrasound. Stones can be retrieved via the ureteroscope with or without disintegrating the stone in situ with a probe.

Lower third ureteric stones

These stones are dealt with by ureteroscopic stone retrieval or ESWL in situ. Ureteroscopic stone retrieval has a high success rate but is more invasive than ESWL.

Bladder stones

If a bladder stone is suspected or seen on an xray then a cystoscopy is required. The stone can be retrieved if it is small enough to come down the telescope. Larger stones need to be disintegrated using a stone punch (litholapaxy).



Bladder stone